



Positively
change
your
approach

The logo features a red curved line above the word 'COMEG' in a bold, black, sans-serif font.
COMEG
medical technologies



ULTRASONIC PIEZO BONE SURGERY
THAT BRINGS CONFIDENCE
TO BOTH SURGEON AND PATIENT



Rhino surgery



Satisfy expectations of the patients

Today, the majority of rhinoplasty requests concern noses that are too large, too wide, or with a bump to correct.

This procedure is considered as one of the most complicated facial surgery for many reasons. Every gesture, every millimeter has an impact on the final result.

For the patients, the fears are no less great and the expectations just as important!

1 - The Role of Piezoelectric Instrumentation in Rhinoplasty Surgery: Olivier Gerbault, MD; Rollin K. Daniel, MD; and Aaron M. Kosi, MD - November 6 2015

2 - Piezotome rhinoplasty reduces postsurgical morbidity and enhances patient satisfaction: A multidisciplinary clinical study. A. Troedhan. YJOMS57235 J Oral Maxillofac Surg 2016

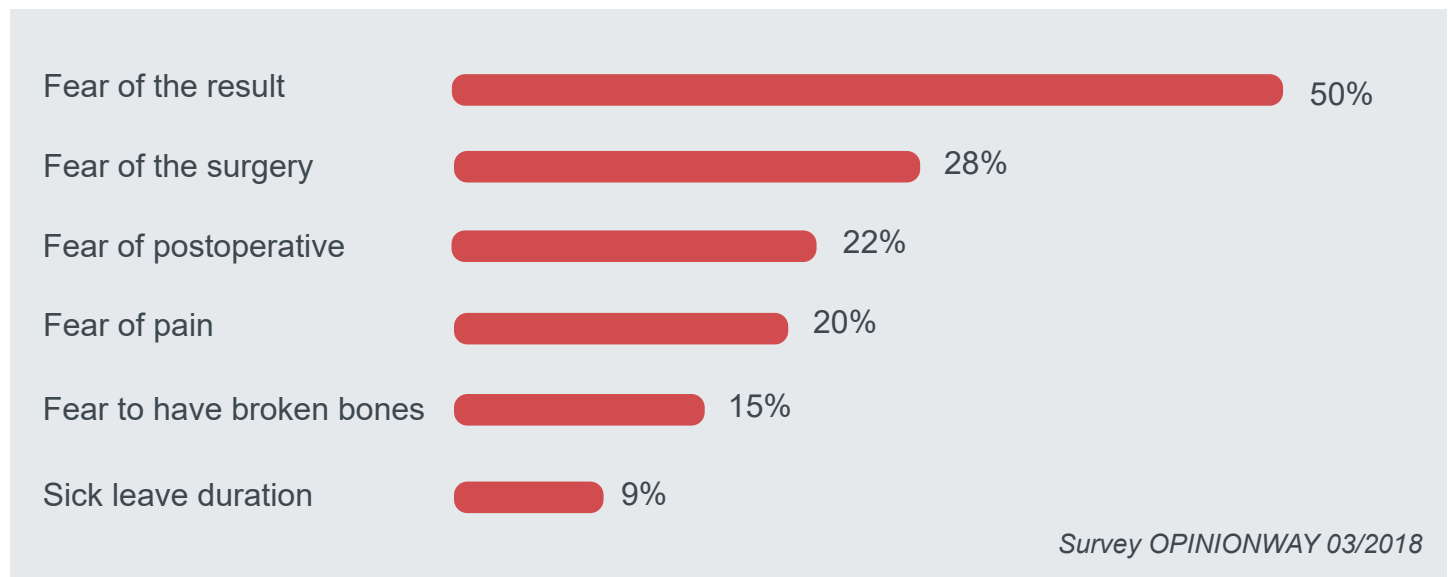
Class IIa and IIb medical devices CE0459 (GMED) according to Medical Device Directive 93/42/EEC depending of products (Class IIa medical devices according to Medical Device Regulation 2017/745) - For medical professional use only.

Manufacturer: SATELEC®, a company of ACTEON Group - 17 avenue Gustave Eiffel, ZI du Phare 33700 MERIGNAC France

Read carefully the instructions for use available on www.satelec.com/ documents

The patient's fears

According to an opinion poll, the main reasons to curb rhinoplasty surgery are:

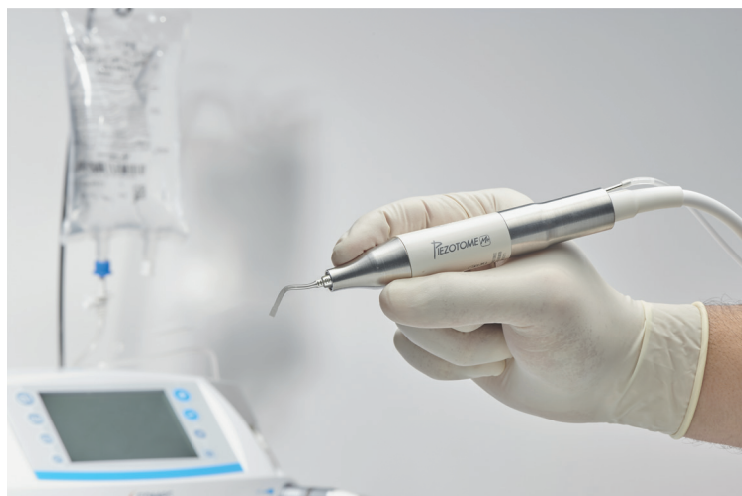

M+ RHINOPLASTY SOLUTION^{1, 2}

The piezoelectric technology benefits have been proven over the years to enhance intraoperative advantages and postoperative outcomes.

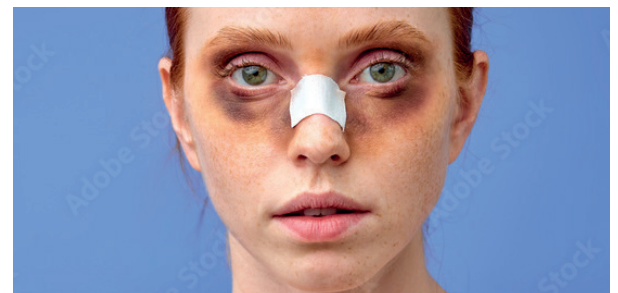Operating room certified, COMEG M+ piezoelectric solution is of growing interest among surgeons: safer clinical procedures, improved healing and alleviate post-surgical pain are the main benefits in using M+.

M+ devices are used for rhinoplastic surgeries where precision, safety and efficacy are a priority. The bone volume is preserved thanks to highly precise cuts, linear tip vibrations, controlled and regular tip amplitude.



In comparison, rhinoplasty with manual instruments is more invasive for the patient and less precise for the surgeon.

The bones are broken blindly. Sometimes the bones don't break where expected, and leads to aesthetic defects that are impossible to hide or even breathing issues.



After manual rhinoplasty



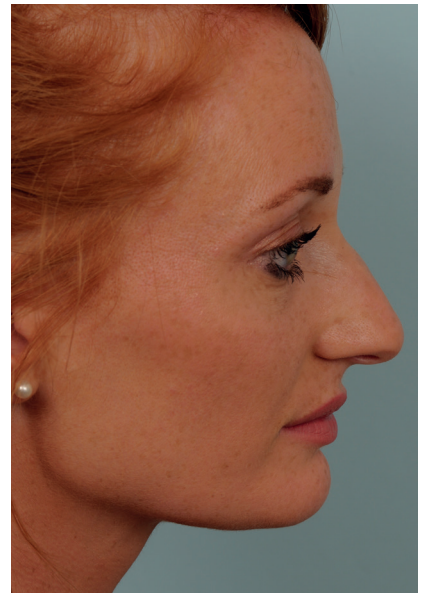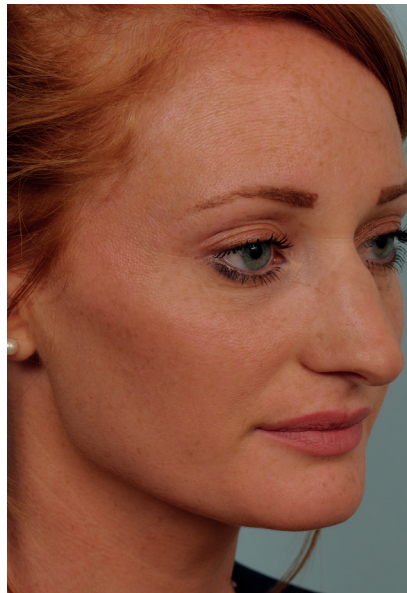6 days after ultrasonic rhinoplasty

Testimony
My Rhino
sculture

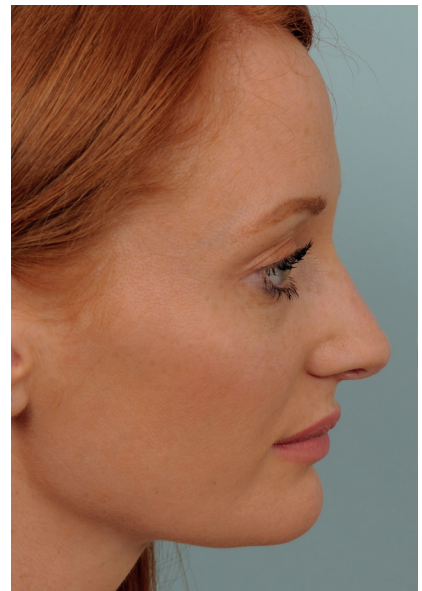


*The precision
of this technique
reasured me*

Before



After 6 month





6 years after surgery

It is a violent operation during which we imagine the surgeon hitting his chisel with a hammer to fracture our nose.

I had already thought of rhinoplasty to correct a hump on my nose, but it scared me. I wanted a less traumatic technique for my nose and for me.

If the operation lasts a little longer, up to three hours to about an hour, the

precision of this technique reassured me. I didn't want a small «American» nose but something natural, which matched the morphology of my face.

I am totally satisfied with the result."

Alexia, Paris, France
alerterousse.com



Listen to her experience on our YouTube COMEG page

Clinical case #1

PRIMARY RHINOPLASTY

PRESERVATION HIGH STRIP TECHNIQUE



Dr. Olivier Gerbault is qualified to the Board of the Association of Physicians in reconstructive and cosmetic plastic surgery. He entered on the roll of the order of the Val de Marne.

Dr. Gerbault is former resident of the Hospitals of Paris and former Chef de Clinique - Assistant (Fellow) at Saint-Louis Hospital (Paris).

He's professor of the International Society of Aesthetic Plastic Surgery (ISAPS) and teaches every month rhinoplasty, especially ultrasonic rhinoplasty, to surgeons coming from all over the world.

Dr. Olivier Gerbault, France

"Preservation techniques of the dorsum have become very popular in recent years, especially for correcting minor humps that are not too asymmetrical and have a favorable shape.

The principle is to avoid opening the upper lateral cartilages and to maintain the osteocartilaginous junction continuity at its central part. Long ultrasonic rhinoplasty instruments play a crucial role in these techniques to precisely control the mandatory septum resection required to lower the cartilaginous or osteocartilaginous vault. They also allow for gentle and controlled harvesting of nasal septum tissue or correction of any type of septal deviation while preserving septal stability."

***Piezoelectric surgery is part
of the current evolutions of
21st century surgery.***



Before



4 months later

This patient complained of a nose that was too long, too masculine, with a moderate hump more pronounced on the left side.

She underwent an open rhinoplastic rhinoplasty combine with a preservation technique.



Before



6 days later



4 months later

The result at 6 days shows moderate swelling and minimal bruising.

The result at 4 months shows the natural correction of the hump and the desired overall refinement of the nose.

Clinical case #2

PRIMARY RHINOPLASTY

FEMINIZATION OF THE NOSE



Dr. Amanda Fanous is a facial plastic surgeon based in Montreal, Canada. Her practice focuses mainly on rhinoplasty (both aesthetic and functional) and facial rejuvenation. She also has a particular expertise in otoplasty.

She completed both her medical school and Otolaryngology-Head and Neck surgery residency at McGill University. She then spent her fellowship in Paris, France, learning from experts in the field including Dr. Olivier Gerbault and Dr. Françoise Firmin.


Dr. Amanda Fanous, Canada

I truly believe that ultrasonic technology has revolutionized the world of rhinoplasty.

"I truly believe that ultrasonic technology has revolutionized the world of rhinoplasty. For the first time in history, rhinoplasty surgeons are now armed with a tool that allows them to not only precisely perform all osteotomies, but to also sculpt the actual bony surfaces (osteoplasty).

Furthermore, given that the piezotome does not breach the inner periosteum, the work has the added advantage of being done under direct visualization for extra precision without fear of bony collapse. The applications are wide: deviated bony pyramids, wide bony vaults, brittle bones in older patients, etc... I could not imagine my practice today without it.


Thank you Dr. Olivier Gerbault for pioneering this technique and thank you COMEG for engineering the perfect tool."



Before

This is a 25 year old woman who presented requesting a primary rhinoplasty to feminize her nose. She is a model and felt that her nose was too imposing for her otherwise delicate facial features.

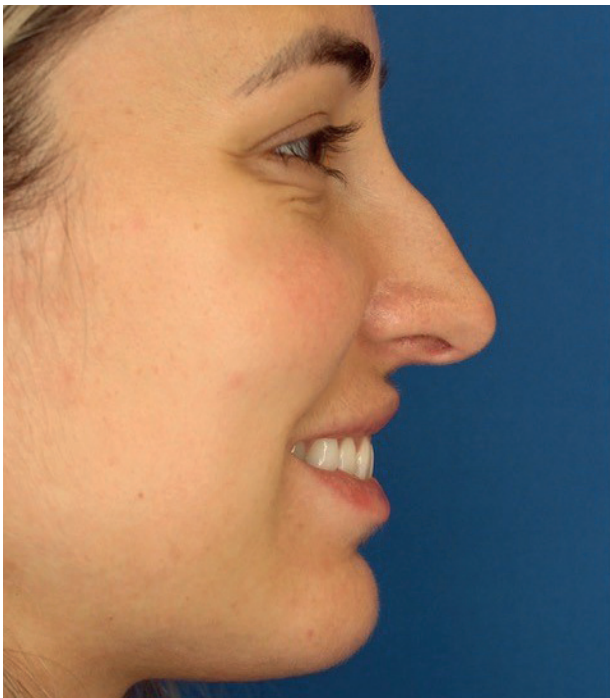She had a large dorsal hump, a deviated and asymmetric bony pyramid, a concurrent septal deviation and a droopy slightly bulbous tip.



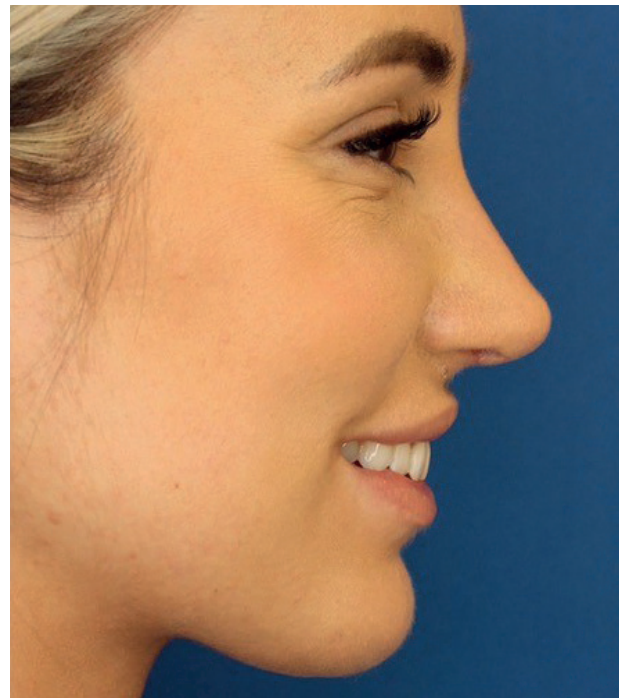
3 months later

The COMEG Piezotome® M+ was used to precisely remove the bony hump and to narrow, straighten and even out her nasal bones.

Furthermore, a complex septal reconstruction as well as tip refining and supporting techniques were undertaken to lift and refine her nasal tip.



Before

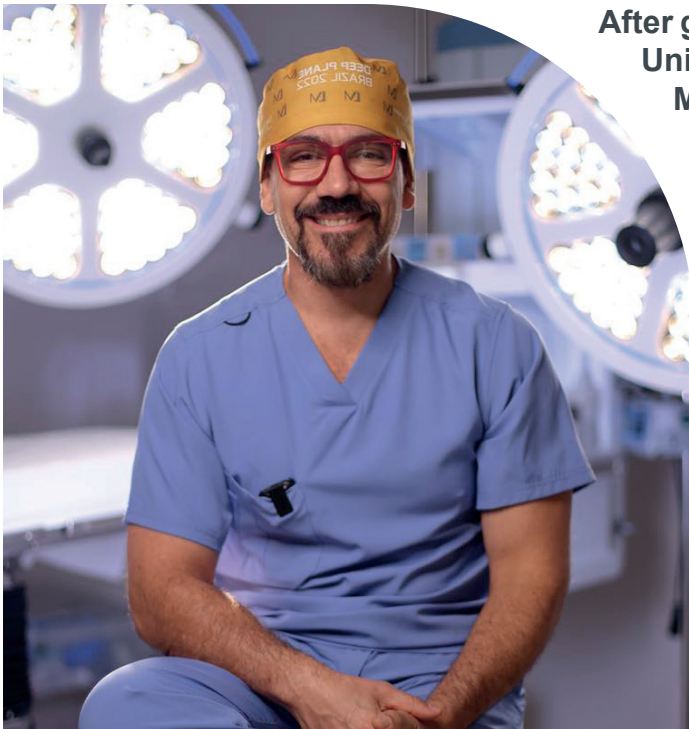


3 months later

Clinical case #3

PRIMARY RHINOPLASTY

STRUCTURED ULTRASONIC RHINOPLASTY WITH COSTAL GRAFT



After graduating in medicine from the Pontifical Catholic University of Campinas (PUC-Camp), Dr Lessandro Martins did his internship at the Federal University of Uberlândia (UFU).

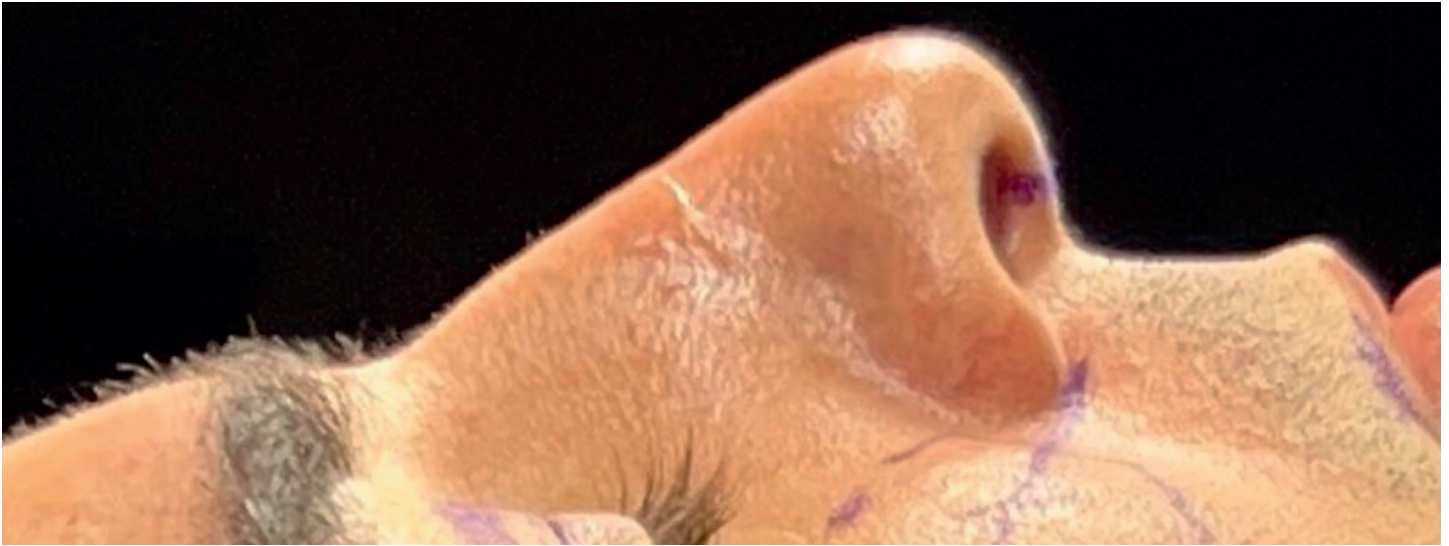
After specializing in otorhinolaryngology, he spent over three months in Bogotá, Colombia, learning from the best nose surgeon at the time, Dr Fernando Pedroza.

He returned to Brazil and worked for two years at the Federal University of Uberlândia as an assistant professor, putting into practice all the experience he had gained during his years of study.

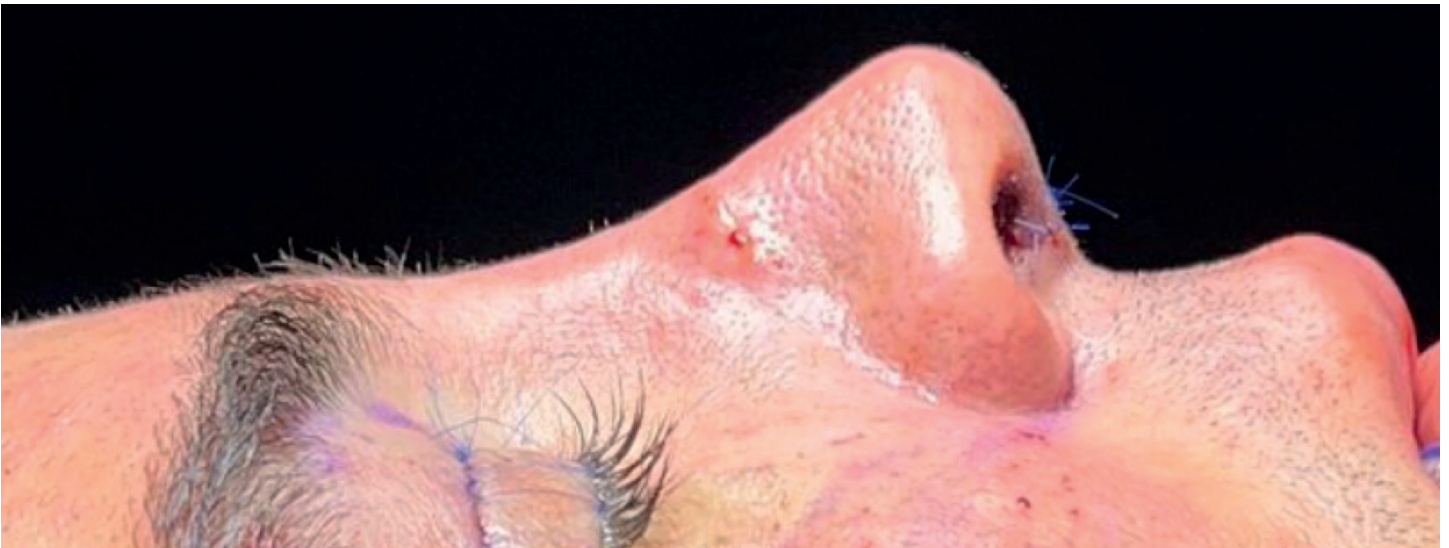
He also has developed techniques that have attracted doctors from all over the world to come and learn from him.

Dr. Lessandro Martins, Brazil

I used COMEG's Piezotome M+ for remodeling and narrowing the bony upper third.



Before



Just after the surgery

**FISH BONE
TECHNIQUE**

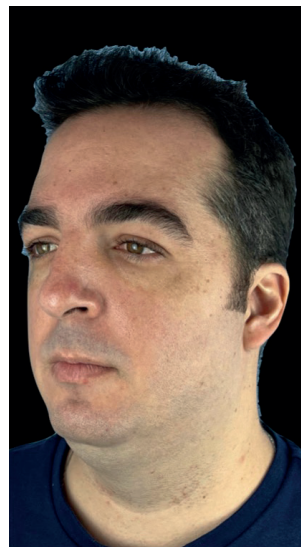"This patient underwent rhinoplasty to correct a dorsal hump, droopy tip and crooked nose.

We've applied the Martins' Rhinoplasty concept, which consists in a structured

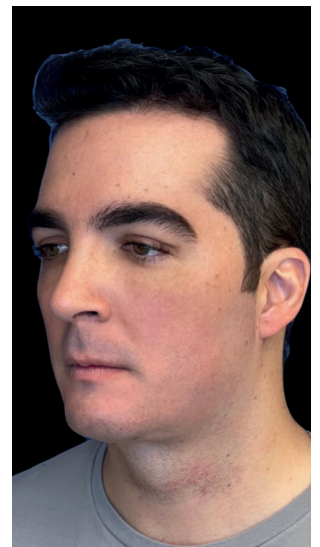
ultrasonic rhinoplasty with costal graft.

In this case was used double spreader and double septal extension graft for structure, osteoplasty and fish bone osteotomies with piezotome for remodeling and narrowing the bony pyramid and upper third, sutures for nose tip reshaping.

You can see that the nose is no longer dropped and he has a natural and straight appearing nasal profile and three quarters."



Before



After

M+ Rhinoplasty Tips

We offer a wide range of tips specially designed for rhinoplasty surgery.

We first launched two kits of short tips aimed for the open approach:

- the **"Essential" kit** composed of the main tips necessary for an efficient ultrasonic rhinoplasty

Ref: F87681

- the **"Expert" kit** composed of the six tips from the "essential" kit and three additional tips allowing a more thorough and precise surgery.

Ref: F87689



RHS2Hb

Hard rasp

For thick skin
or dense bone

*Fine remodeling of the nose pyramid.
Removal of the bony hump and lateral convexity.
Smoothing of bone irregularities.
Smoothing of bone and hard cartilaginous graft.*

Tip length: 33.7 mm
D1 - 60 ml/min - 3*

- Ref: F87686



RHS2Fb

Fine rasp

For thin skin
or thin bone

*Fine remodeling of the nose pyramid.
Removal of the bony hump and lateral convexity.
Smoothing of bone irregularities.
Smoothing of bone and hard cartilaginous graft.*

Tip length: 33.7 mm
D1 - 60 ml/min - 3*

- Ref: F87687



RHS6

Diamond coated drill

Nasal bone or nasal spine drilling

*Septal suture to bone.
Bone suture.*

Tip length: 27 mm
D1 - 80 ml/min - 3*

- Ref: F87680



RHS5

Straight thin saw

Median oblique osteotomy

*Low osteotomy.
Medial oblique osteotomy to connect the transverse osteotomy to the external part of the hump resection.
Costal bone harvesting.*

Tip length: 34 mm
D1 - 60 ml/min - 3*

- Ref: F87679



"ESSENTIAL"

Kit



RHS3L/RHS3R

Left and Right angled saws
Lateral or transversal osteotomies

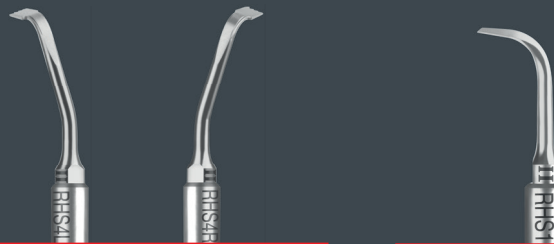*Lateral osteotomies:
From the pyriform aperture to the top of
the nasofacial groove.
Transverse osteotomy.*

Tip length: 30 mm
D1 - 60 ml/min - 3*

• Ref: F87677 / F87678

"EXPERT"

Kit



RHS4L/RHS4R

Left and Right angled saws

Lateral or transversal osteotomies
*Transverse osteotomy:
After the lateral osteotomy
to reach the medial part of
the bony vault.
Costal bone harvesting.*

Tip length: 31.5 mm
D1 - 60 ml/min - 3*

• Ref: F87683 / F87682

RHS1

Scraper
Remove important bone excess

*Remodeling of the
nose pyramid:
Osteotomy of the
dorsal hump and
lateral convexity.*

Tip length: 28 mm
D1 - 60 ml/min - 3*

• Ref: F87688

* Maximum fine settings - Available only with Implant Center M+ and Piezotomoe M+ devices - Available in non sterile version only



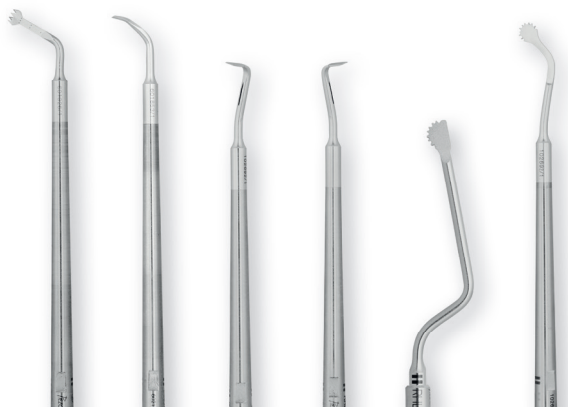The

NEW

COMPLETE AND
DEDICATED

Range

*developped in collaboration
with Dr Olivier Gerbault*





Pionners in ultrasonic rhinoplasty since 2015, we are now going further in supporting practitioners and their patient's well-being.

To best support the development of new techniques such as **Preservation Rhinoplasty**, we worked with experts to develop a **new range of long tips**.

Each tip has been designed specifically to respect the anatomy and answer to the different steps of bone treatment in rhinoplasty, from bone rasping to osteotomies with a completely unobstructed and clear view. Thus, any bone convexity or asymmetry can be assessed and treated.

Inspired by practioners, dedicated to their patients.

NEW

M+ RHINOPLASTY

Long tips

As the rhinoplasty techniques evolve, our range of tips also changes with the arrival of **long tips**.

All kinds of ultrasonic rhinoplasty surgeries can now be performed thanks to the most complete and various range of tips from COMEG.

EW NEW
EW NEW
EW NEW
EW NEW
EW NEW
EW NEW
EW NEW
EW NEW
EW NEW
EW NEW
EW NEW
EW NEW
EW NEW
EW NEW
EW NEW
EW NEW
EW NEW
EW NEW
EW NEW
EW NEW
EW NEW
EW NEW



BS1 XXL

Extra long thin saw

Median oblique osteotomy

*Medial oblique osteotomies.
Costal bone harvesting.*

Tip length: 104 mm
D1 - 80 ml/min - 3*

• Ref: F87602



BS6 XXL

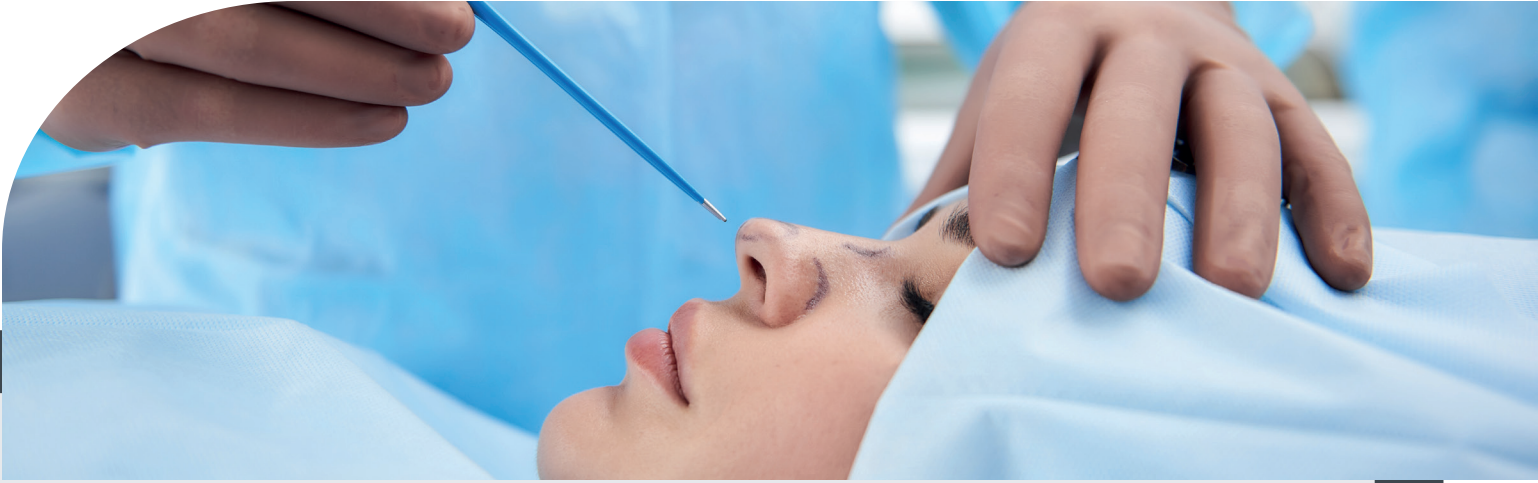
Extra long scraper

Remove important bone excess

*Remodeling of the nose pyramid :
Ostectomy of the dorsal hump and lateral convexity.*

Tip length: 103 mm
D1 - 80 ml/min - 3*

• Ref: F87604



RHL4L/RHL4R**

Extra long angled saws

Lateral or transverse osteotomies

*Transverse osteotomies.
Longitudinal osteotomy of the perpendicular blade of the ethmoid.*

Tip length: 91.7 mm

D1 - 60 ml/min - 3*

• Ref: F87692 / F87691



RHL5**

Long thin saw

Median oblique, cephalic and caudal osteotomies

*Medial oblique osteotomy.
Dorsal resection of the bony and cartilaginous septum.
High osteotomy of the perpendicular ethmoidal plate.
Anterior nasal spine osteotomy.*

Tip length: 59.6 mm

D1 - 60 ml/min - 3*

• Ref: F87684



RHL6**

Extra long rounded saw

Anterior osteotomy

*Lateral osteotomies.
Codal resection of the bony and cartilaginous septum.*

Tip length: 101.4 mm

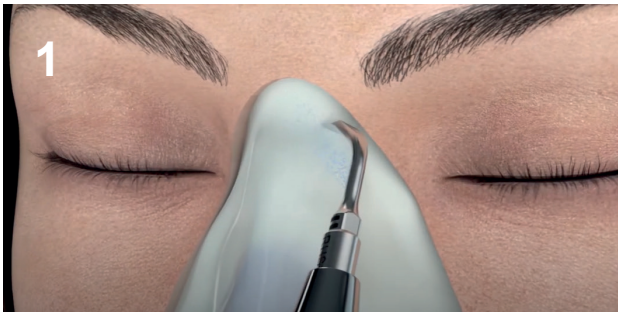D1 - 80 ml/min - 3*

• Ref: F87693

* Maximum fine settings - Available only with Implant Center M+ and Piezotome M+ devices - Available in non sterile version only
**Please contact us to find out the availability of the product in your country.

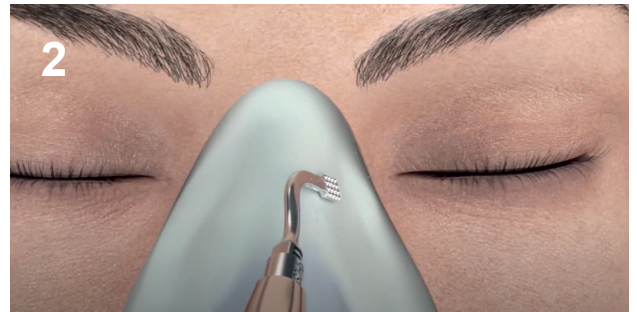
Protocols

OPEN TECHNIQUE with Rhinoplasty Expert kit



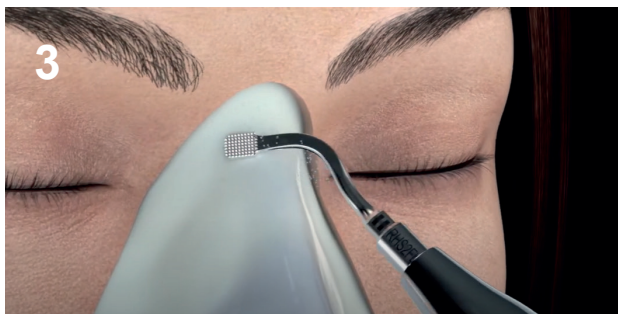Osteotomy of the dorsal hump and lateral convexity.

- RHS1



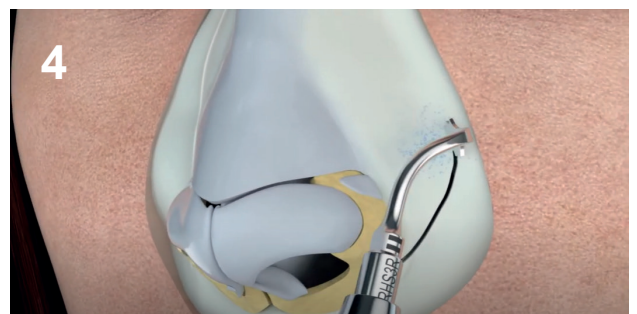Rasping of the dorsal hump and lateral convexity.

- RHS2Hb



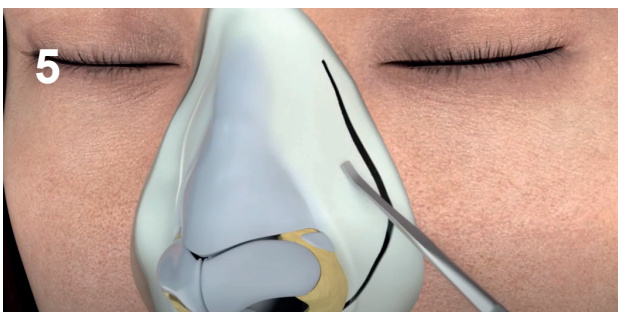Smoothing of the bones with the fine rasp.

- RHS2Fb

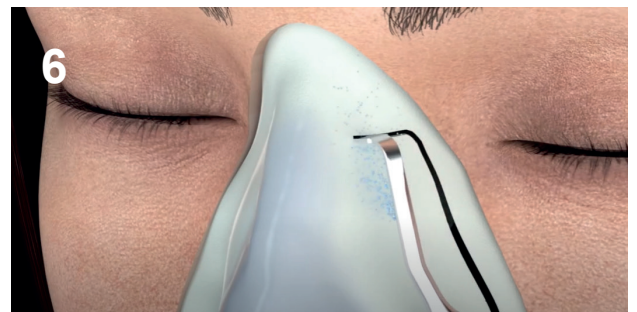

Lateral osteotomy from the pyriform aperture to the cephalic part of the naso facial groove

- RHS3R

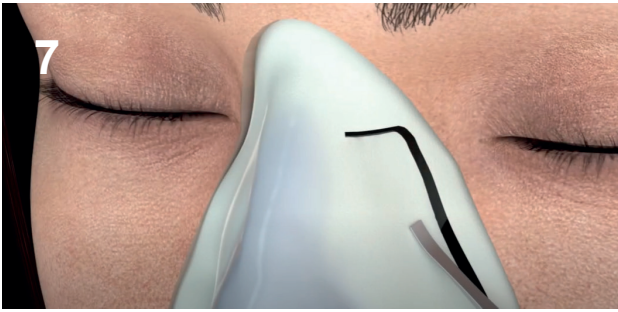


Bone mobility assessment

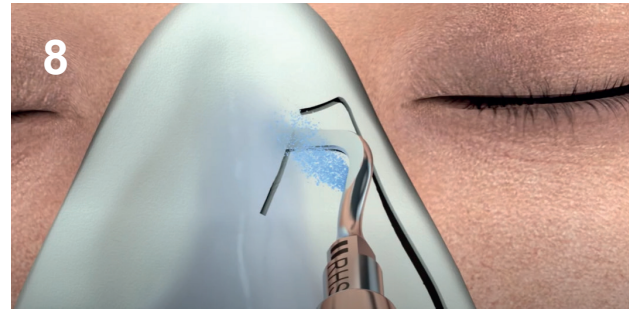


Transverse osteotomy

- RHS4R

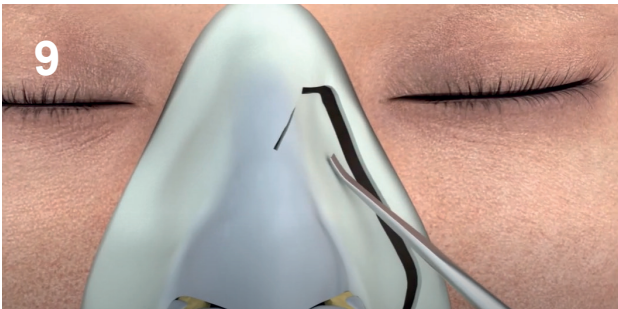

Bone mobility assessment

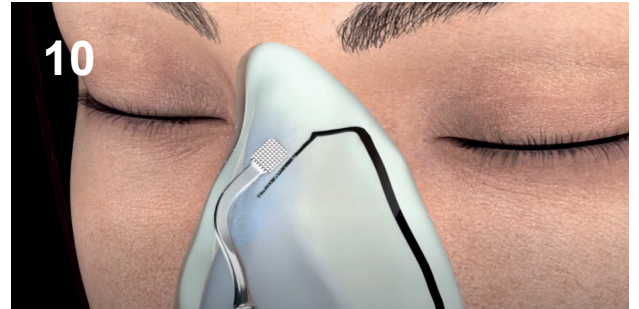

Median oblique osteotomy if mobility is not achieve

- RHS5



Bone mobility assessment



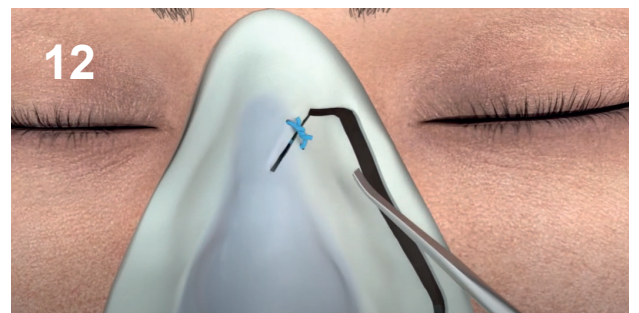
Rasping bones edges

- RHS2Fb



Holes drilled if there is a significant gap between the two sides of the osteotomy line of a lack of bone stability

- RHS6



Final bones positioning

Replicate the same protocol on the right side.



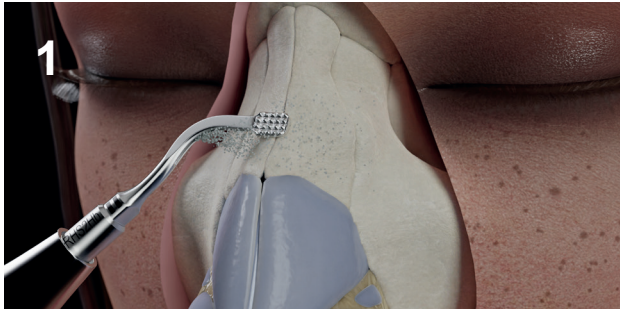
*3D tutorial on our
YouTube COMEG page*

NEW

M+ RHINOPLASTY

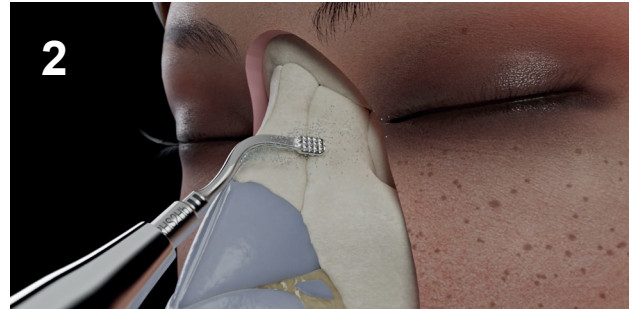
Long tips

PRESERVATION RHINOPLASTY HIGH STRIP OPEN APPROACH



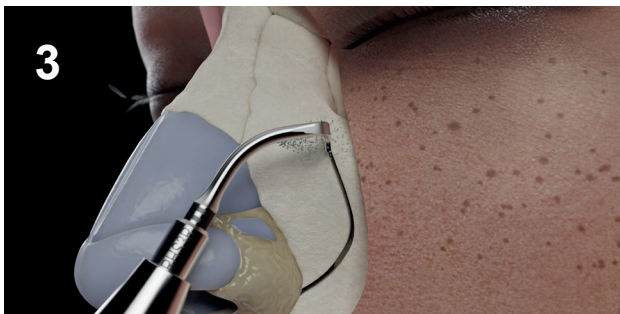Abrasion of the bony vault for better skin adhesion

- RHS2Hb



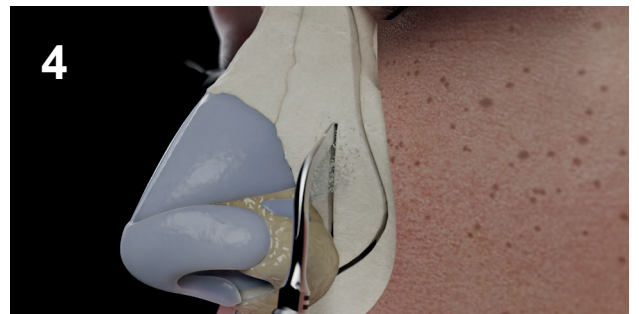
Rasping of the hump and the lateral convexity

- RHS2Hb



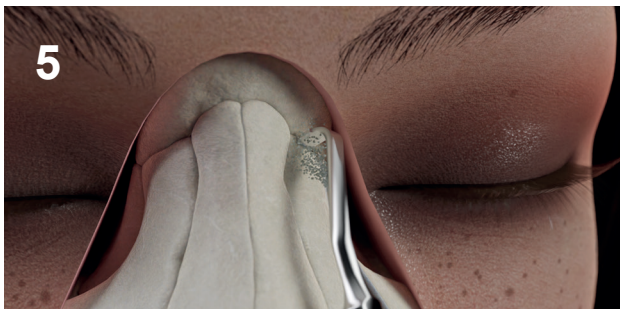Lateral osteotomy from the pyriform aperture till the highest part of the ascending branch of the maxilla

- RHS3R



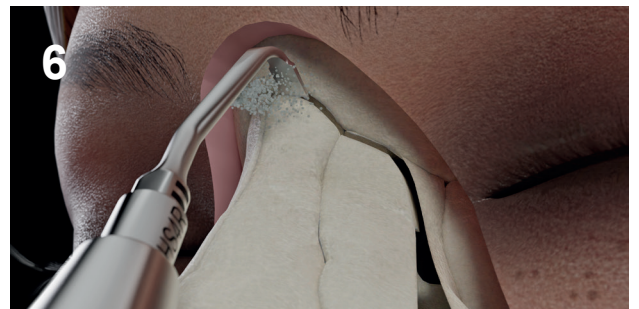
Let down option: Controlled osteotomy of the sidewalls removing a wedge of bone

- RHS5



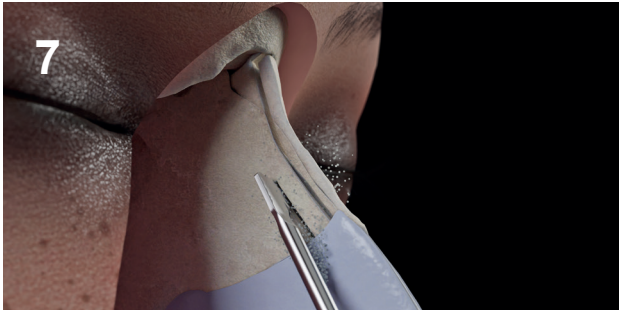
Transverse osteotomy*

- RHS4R



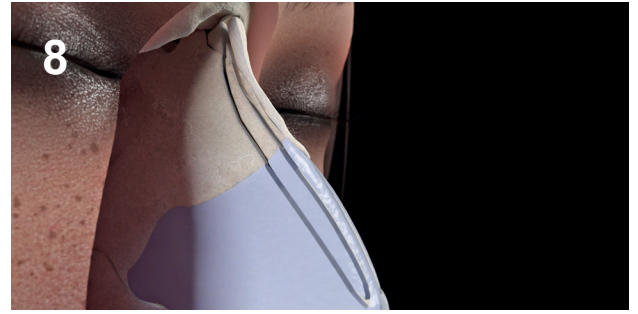
Radix osteotomy left side*

- RHS4R

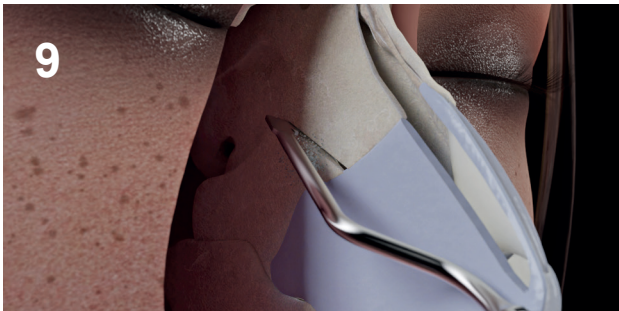


Osteotomy of the perpendicular plate of the ethmoid joining the radix osteotomy

- RHL5




Septal strip trimming continued with a knife



When graft harvesting is necessary for tip support: bone and cartilage septum harvesting

- RHL5



Continue the bone and cartilage septum harvesting

- RHL6



Continue the bone and cartilage septum harvesting

- RHL4L



Continue the cartilaginous septal trimming with a knife



**Same protocole on the other side of the patient*

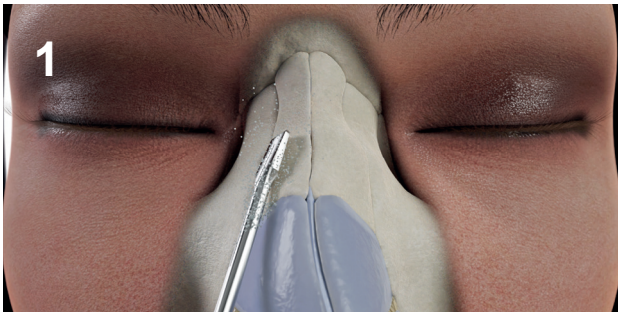*3D tutorial on our
YouTube COMEG page*

NEW

M+ RHINOPLASTY

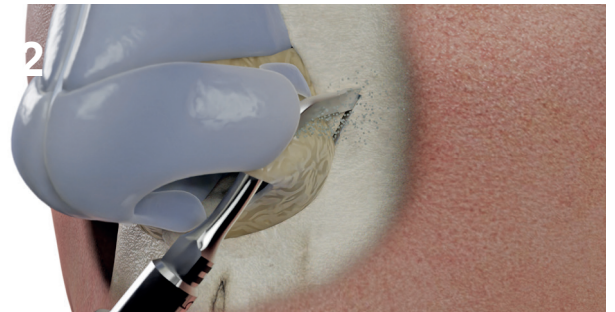
Long tips

PRESERVATION RHINOPLASTY LOW STRIP CLOSED APPROACH



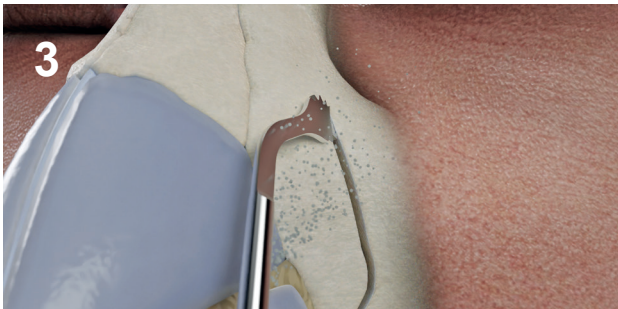
1
Abrasion of the bony vault for better skin adhesion

- RHL2



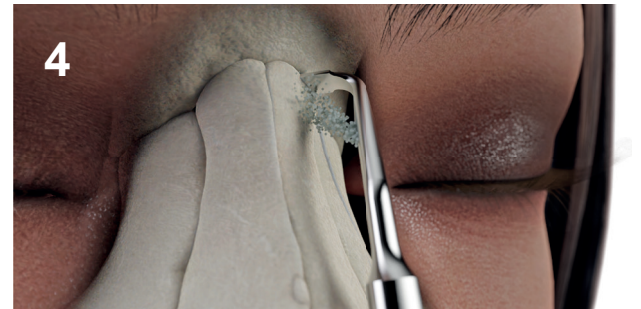2
Lateral osteotomy from the pyriform aperture.

- RHS5



3
Continue till the highest part of the ascending branch of the maxilla.

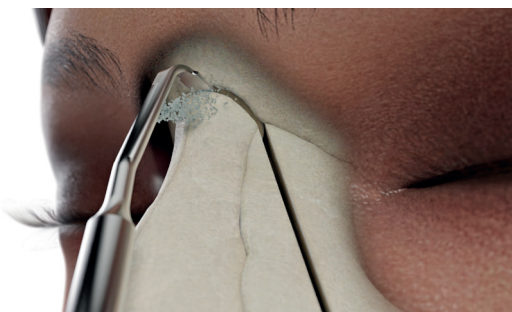- RHL6



4
Transverse osteotomy.

- RHL4R

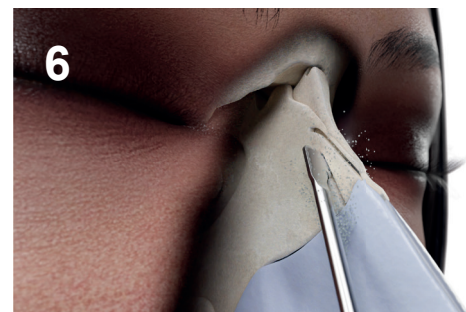Same protocole on the other side.



Radix osteotomy left side.

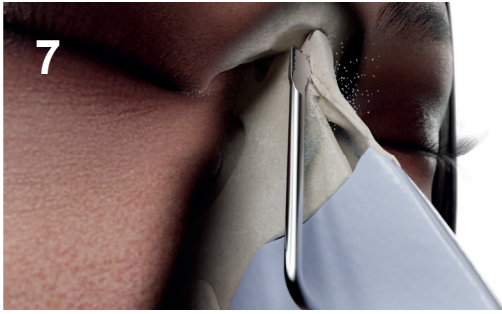- RHL4R

Same protocole on the other side



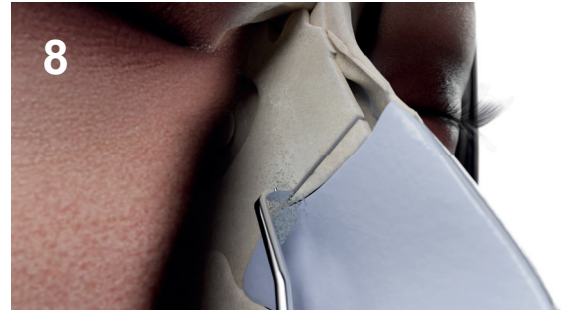6
Dorsal resection of the bony and cartilaginous septum.

- RHL5 + RHL4L



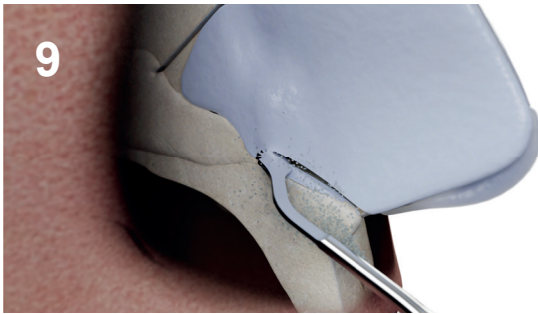
Join the radix osteotomy.

- RHL5



Longitudinal osteotomy of the perpendicular plate of the ethmoid.

- RHL4L



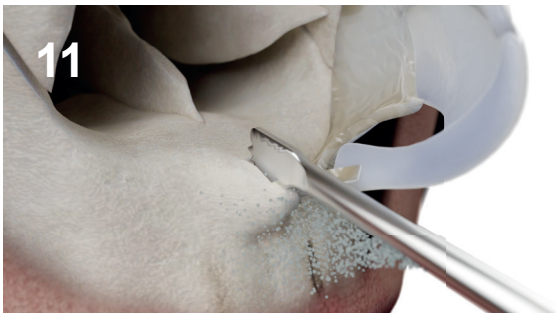Codal resection of the bony and cartilaginous septum.

- RHL6



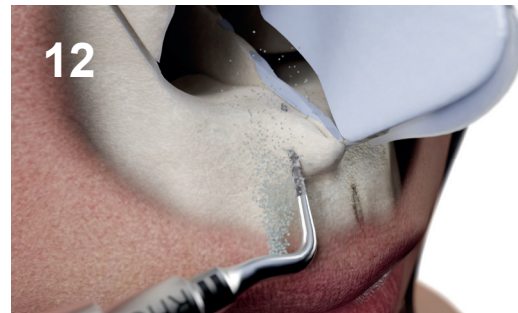Continue the cartilaginous septal trimming with a knife.

Lowering of the bone pyramid.



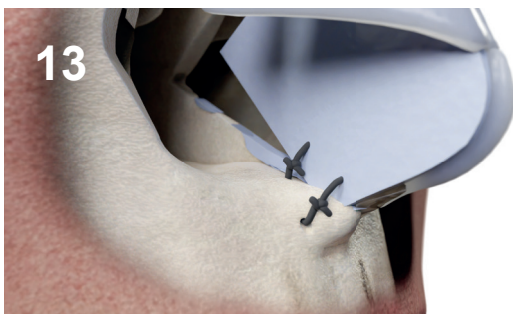Anterior nasal spine osteotomy.

- RHL5



Holes drilled on both sides of the nasal spine.

- RHS6



Suture the septum and pull on the threads to stabilise it.

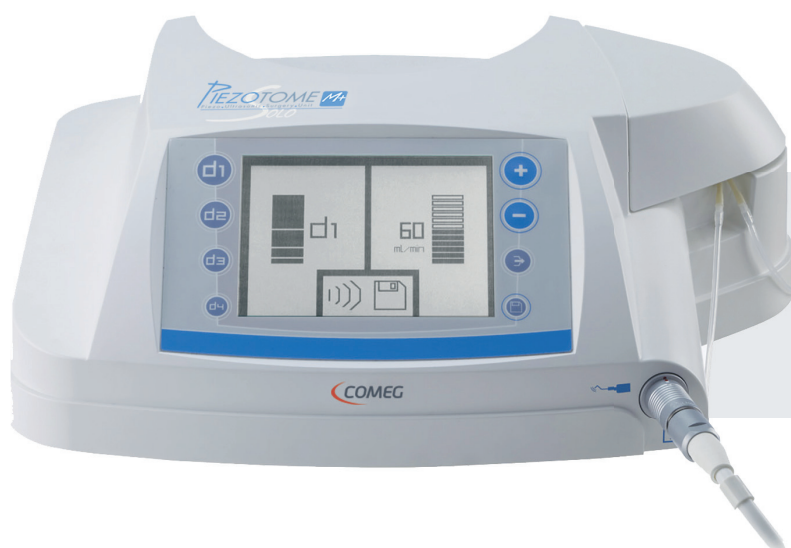

*3D tutorial on our
YouTube COMEG page*

M+ Solution


A COMPLETE RANGE FOR
A COMPLETE EXPERTISE

PIEZOTOME® SOLO M+



- Ref CEE: F57850
- Ref UK: F57850
- Ref AUS: F57853
- Ref US: F57856

PACK M+



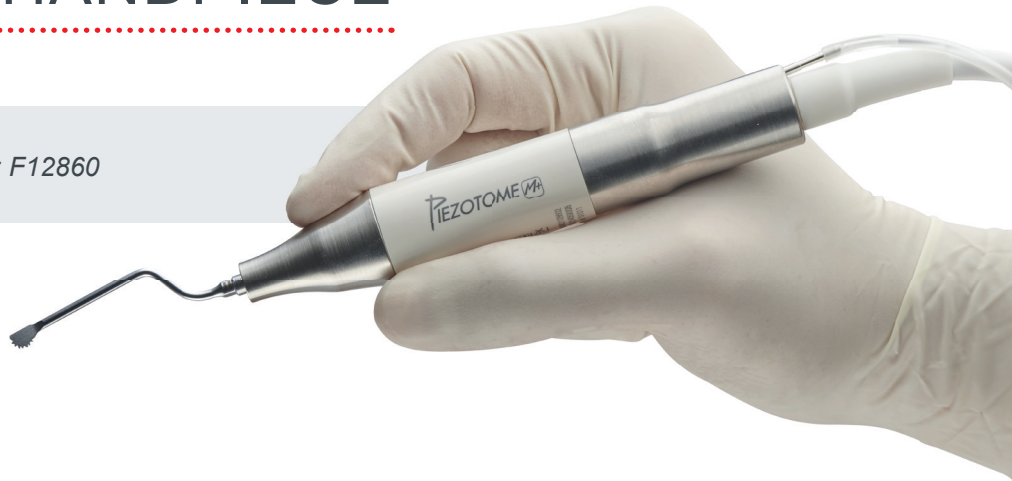- Ref: F57802

Included:

- Hand piece M+ x1
- M+ flat key x1
- Protected sleeve M+ x2
- Autoclavable cassette M+ x1

PIEZOTOME M+ HANDPIECE

• Ref: F12860



IRRIGATION LINE M+

Set of disposable sterile line(s)
With clips and perforators

• Ref: F59925 x5
• Ref: F59926 x1



PROTECTIVE SLEEVE M+*

M+ Protective sleeve
For extra long tips

• Ref: F87903*



PIEZOTOME® SOLO M+ FOOTSWITCH

• Ref: F57851





SATELEC

A company of ACTEON Group

17 Av. Gustave Eiffel,
ZI Phare
33700 Mérignac
France



info@comegmedical.com

www.comegmedical.com

Reference document: Non contractual document - Ref. D88005 - 10/2023 - Copyright © 2023 SATELEC. All rights reserved.
No information or part of this document may be reproduced or transmitted in any form without the prior permission of SATELEC.

